# Effect of Microfracture on Meniscal Tear Healing in a Goat (*Capra hircus*) Model

William R. Howarth, MD; Kevin Brochard, MD; Scot E. Campbell, MD; Brian F. Grogan, MD

## abstract

Meniscal injuries are an extremely common cause of knee pain. Meniscal repairs performed with concomitant anterior cruciate ligament reconstruction appear to heal at a higher rate than meniscal repairs performed in isolation. This may be due in part to the release of marrow elements into the knee and the time of meniscal repair. In cases of isolated meniscal repair, some orthopedic surgeons use microfracture to release marrow elements into the joint as an adjunct to enhance meniscal healing. This study evaluated rates of meniscal tear healing with or without the performance of microfracture in a goat (*Capra hircus*) model. Forty castrated young adult male goats underwent either a horizontal or a longitudinal 1.0-cm meniscal tear with or without microfracture. All procedures were performed open, in a bloodless field. Meniscal tears were created in the peripheral half of the body of the medial meniscus. The goats were euthanized at 6 months, and meniscal tears were analyzed and classified as complete healing, partial healing, or no healing by direct visualization. A probe was used as an aid to evaluate and classify the meniscal tears. Twenty (87%) of 23 goat meniscal tears showed at least partial healing when performed with concomitant microfracture. Only 5 (29%) of 17 menisci showed any healing in goats that did not receive microfracture. This difference in healing rates was statistically significant ($P<.001$). Fifteen (65%) meniscal tears accomplished with microfracture were completely healed, whereas only 2 (12%) menisci showed complete healing without microfracture ($P<.001$). The results of this study suggest that the release of bone marrow elements into the knee by microfracture improves meniscal healing rates. [*Orthopedics*. 2016; 39(2):105-110.]

Meniscal injuries are an extremely common cause of knee pain. The human meniscus is a semilunar fibrocartilaginous structure that is found on the medial and lateral sides of the knee. It is critical to the overall health and function of the knee.[1,2] The meniscus absorbs impact and protects the articular cartilage during load-bearing activity.[1,2] Additionally, the meniscus provides joint stability, proprioception, and articular cartilage nutrition, and it has a significant effect on knee biomechanics.[1,3] After meniscal injury, knee biomechanics are altered and degenerative changes often occur within

*The authors are from the Department of Orthopedic Surgery (WRH), US Air Force Academy, Colorado Springs, Colorado; the Department of Orthopedic Surgery (KB), New England Baptist Hospital, Boston, Massachusetts; the Department of Radiology (SEC), Landstuhl Regional Medical Center, Landstuhl, Germany; and the Department of Orthopedics and Rehabilitation (BFG), Carl R Darnall Army Medical Center, Fort Hood, Texas.*

*The authors have no relevant financial relationships to disclose.*

*This study was funded by the Wilford Hall Medical Center Institutional Animal Care and Use Committee (IACUC) and the US Government.*

*The views expressed in this manuscript are those of the authors and do not reflect the official policy of the US Air Force, US Army, Department of Defense, or US Government. Drs Howarth and Grogan are employees of the US Government. This work was prepared as part of their official duties, and as such, there is no copyright to be transferred.*

*Correspondence should be addressed to: Brian F. Grogan, MD, Department of Orthopedics and Rehabilitation, Carl R Darnall Army Medical Center, 3600 Darnall Loop, Fort Hood, TX 76544-4752 (brian.f.grogan.mil@mail.mil).*

*Received: April 12, 2015; Accepted: July 22, 2015.*

*doi: 10.3928/01477447-20160119-04*

Table 1

**Group Randomization by Type of Tear and Category of Microfracture**

| Group | Type of Tear | Micro-fracture | No. of Goats |
|---|---|---|---|
| 1 | Longitu-dinal | No | 10 |
| 2 | Longitu-dinal | Yes | 11 |
| 3 | Hori-zontal | No | 7 |
| 4 | Hori-zontal | Yes | 12 |

the tibiofemoral compartments.[1,4,5] Increased tibiofemoral arthrosis after surgical meniscectomy has been shown in several long-term clinical studies.[4-8]

Injured menisci are often treated with arthroscopic partial meniscectomy, even though meniscus-deficient knees have been associated with degenerative osteoarthritis. Before 2006, arthroscopic partial meniscectomy was the most commonly performed procedure among all cases presented for Part II of the American Board of Orthopedic Surgeons certification examination.[9,10] With increasing recognition of the importance of the meniscus in knee biomechanics, multiple meniscal repair techniques have been developed. Additionally, multiple healing adjuncts have been proposed to enhance meniscal healing. Despite advances in meniscal repair techniques and biologic adjuncts, a systematic review by Nepple et al[11] showed a meniscal repair failure rate of 22% to 24% at 5 years.

Meniscal repairs performed with concomitant anterior cruciate ligament (ACL) reconstruction appear to heal at a higher rate than meniscal repairs performed in isolation.[12,13] Cannon[12] found a 93% healing rate in menisci repaired with ACL reconstruction vs a 50% success rate in meniscal repairs performed on stable knees that did not require ACL reconstruction.[12] In addition to improving the stability of the knee with ACL reconstruction, the authors believe that the hemarthrosis that occurs after creation of bone tunnels during ACL reconstruction provides a fibrin clot and an environment rich with factors that promote healing of the newly repaired meniscus.[12,14-17] The fibrin clot provides a structural foundation for meniscal healing.[13,16,18] Important signaling factors, such as fibronectin and platelet-derived growth factor, have also been identified.[13,19] These factors promote meniscal healing by allowing meniscal fibrochondrocytes to proliferate and synthesize the extracellular matrix.[19]

Microfracture is a common procedure for the treatment of articular cartilage defects in the knee. This procedure is used to stimulate fibrocartilage production over an area of articular cartilage deficiency.[20] Some orthopedic surgeons also use microfracture as an adjunct to enhance meniscal healing at the time of meniscal repair. Microfracture is performed with an awl that creates 1 or more small (measuring 1 to 3 mm) channels that penetrate the subchondral bone and release marrow elements into the joint. This promotes the formation of fibrocartilage over the cartilage defect.[1,20] The factors involved in creation of the fibrocartilage may be the same factors that are responsible for improved meniscal healing rates in patients undergoing meniscal repair with concomitant ACL reconstruction. Both procedures stimulate bleeding from subchondral bone. The authors are unaware of any study that has directly evaluated meniscal healing rates in meniscal tears compared with tears with concomitant microfracture. The goal of this study was to evaluate the effect of microfracture on rates of meniscal healing in a goat (*Capra hircus*) model. The authors hypothesized that the rate of meniscal healing would be higher in goats that underwent microfracture than in goats that did not undergo microfracture 6 months from the creation of a meniscal injury.

## Materials and Methods

The goat is an accepted animal model that was used in previous studies as a correlate to the human knee.[18,21-27] Institutional review board and Institutional Animal Care and Use Committee approval was obtained. For this study, 40 young adult male castrated goats were purchased from a licensed dealer, according to US Department of Agriculture regulations. The goats were randomized to 1 of 4 groups: longitudinal meniscal tear (n=10), longitudinal meniscal tear with microfracture (n=11), horizontal meniscal tear (n=7), and horizontal meniscal tear with microfracture (n=12) (**Table 1**). All meniscal tears were standardized to 1 cm in length (twice the size of a standard No. 15 blade). An open approach was used to create a tear in the peripheral half of the medial meniscus. Microfracture was defined as penetration of subchondral bone, causing marrow elements to enter the joint. Goats that were randomized to undergo microfracture had 5 total microfractures (or subchondral penetrations). Microfracture was performed with a standard 45° awl. In these goats, 3 microfractures were performed in the intercondylar notch and 2 microfractures were created on the edge of the medial femoral condyle. In all cases, a bloodless field was maintained with electrocautery throughout the procedure.

### Surgical Technique

Each goat was anesthetized with weight-based intramuscular ketamine and atropine, intubated, and maintained on inhalational anesthesia (1% to 2% isoflurane). The goat was then positioned supine on a custom surgical table. The right hind limb was used in all cases. The surgical site was shaved preoperatively. The knee was prepared and draped in sterile fashion. Each goat was given 1 g ceftriaxone intramuscularly before the procedure and 1 g after the procedure. A standardized medial approach was used. A 6-cm medial incision was made directly over the deep medial collateral ligament (MCL). The


Copyright © SLACK Incorporated

MCL is located approximately 2 cm from the medial edge of the patellar ligament (**Figure 1**). After the initial skin incision, electrocautery was used to achieve hemostasis. The deeper fascial plane ("sartorial fascia") was identified and incised longitudinally directly over the MCL (**Figure 2**), and the MCL was easily identified (**Figure 3**).[21,23,24,26,27] Previous goat studies used a bone block attached to the distal MCL to gain access to the joint.[21,23,24,26,27] This procedure may allow bone marrow elements to enter the joint and obscure the effect of microfracture on meniscal healing. Therefore, the MCL was transected midsubstance. To maintain the anatomy of the MCL after transection, a Krackow-type stitch was placed through the proximal and distal portions of the MCL with 0 Ethibond (Ethicon, Somerville, New Jersey) sutures to facilitate repair (**Figure 4**). The MCL was then transected with a No. 15 blade. A transverse incision was made in the knee capsule, just proximal to the meniscus, at the joint line. Care was taken to avoid injuring the meniscus or significantly disrupting its blood supply. After the capsule was incised, the entire body of the meniscus was exposed. Visualization was improved with valgus force on the joint. Meniscal tears were created in either a longitudinal or a horizontal fashion (according to randomization assignment) with a No. 15 blade (**Figure 5**). The length of each meniscal tear was twice the size of a standard No. 15 blade (1 cm).

Goats that were randomized to undergo microfracture had the procedure performed in both the intercondylar notch off the weight-bearing surface (3 microfracture holes) and in the distal intracapsular but extra-articular portion of the medial femoral condyle (2 microfracture holes). A total of 5 microfracture holes were created in each joint. Bone marrow contents were visualized oozing from each of the microfracture holes.

All joints were closed in layers. The capsule was closed with 0 Vicryl (Ethicon) sutures. The MCL was repaired by opposing the cut ends and tying the previously placed proximal and distal Krackow stitches. The stability of the knee was then checked with valgus force in both extension and slight flexion. The subcutaneous layer was closed with 2-0 Vicryl sutures, and the skin was closed with 3-0 Monocryl (Ethicon) sutures. Bacitracin was applied to the incision.

The goats were not braced. They were housed in a holding area after surgery for 1 week and then released into a pasture, where they were allowed to move freely, for the remainder of the study. The goats were euthanized 6 months after surgery. The right hind limb was dissected, and each medial meniscus was removed and evaluated for healing. Evaluators were blinded to the surgical technique before gross examination of the specimens. A probe was used to enter the tear in an attempt to penetrate and/or distract the tear, simulating second-look arthroscopy. If the

**Figure 1:** Photograph showing an incision that is approximately 6 cm long. The incision is centered over the medial collateral ligament, with equidistant arms proximal and distal to the joint. The joint line is marked with a dotted line.

**Figure 2:** Photograph showing the superficial medial collateral ligament after transaction. The ligament is being held with forceps.

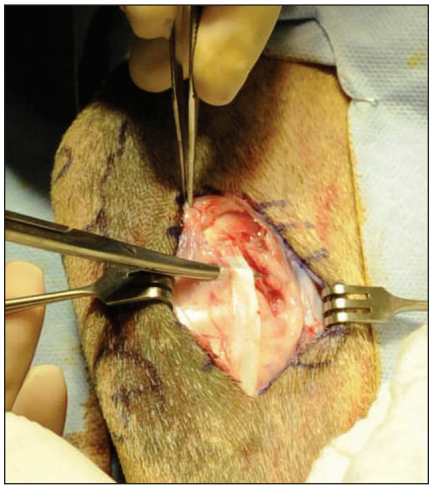

**Figure 3:** Photograph showing the deep medial collateral ligament elevated with dissecting scissors.

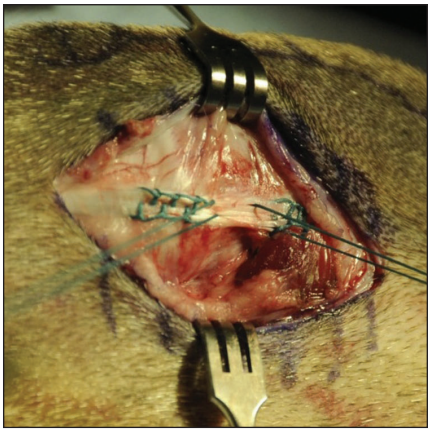

**Figure 4:** Photograph showing a Krackow-type stitch that is placed before the medial collateral ligament is cut.

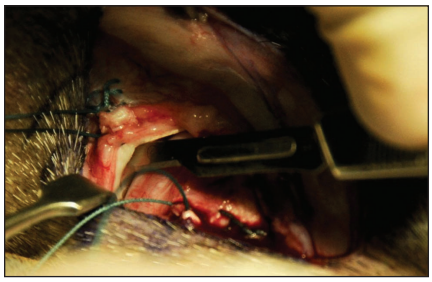

**Figure 5:** Photograph showing creation of a meniscal tear.

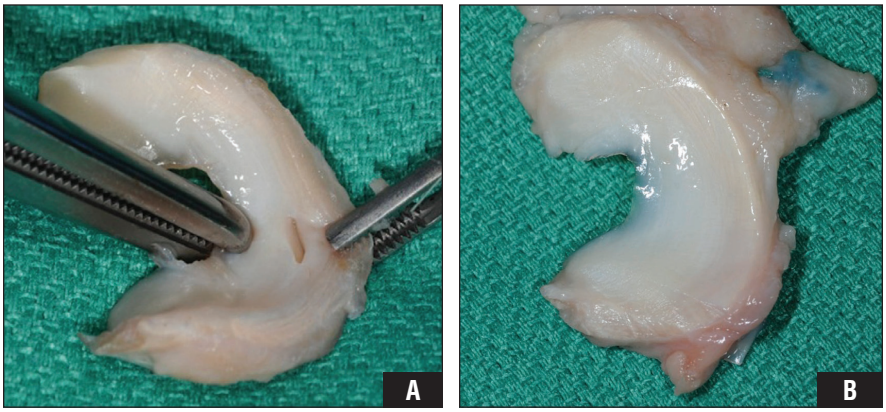


**Figure 6:** Photographs showing an unhealed meniscus tear (A) and a healed meniscus tear (B).

Table 2

**Meniscal Tear Healing**

| | No. | | | | | |
|---|---|---|---|---|---|---|
| Microfracture | Goats | Complete Healing | Partial Healing | No Healing | Complete or Partial Healing | Complete Healing |
| No | 17 | 2 | 3 | 12 | 29% | 12% |
| Yes | 23 | 15 | 5 | 3 | 87% | 65% |

probe passed completely through the meniscus, the meniscal tear was classified as no healing. If the probe passed partially through the tear, the tear was classified as partial healing. If the probe did not penetrate the tear, the tear was classified as complete healing. This classification is similar to the classifications used in previous second-look arthroscopy studies.[17,28,29] Photographs were taken of each specimen (**Figure 6**).

### Statistical Analysis

A Pearson chi-square test was used to compare groups that underwent microfracture with those that did not undergo microfracture (**Table 2**). Additionally, chi-square analysis comparing horizontal and longitudinal tears was performed.

## Results

At 6 months after surgery, 40 goats were available for evaluation, and all underwent necropsy. The microfracture groups (groups 2 and 4) were compared with the nonmicrofracture groups (groups 1 and 3). Of 23 meniscal tears that were created with concomitant microfracture, 20 (87%) showed at least partial healing. In comparison, only 5 of 17 (29%) meniscal tears that were created without microfracture showed complete or partial healing. This difference was statistically significant ($P<.001$). Additionally, only 2 of 17 (12%) meniscal tears without microfracture showed complete healing, and 15 of 23 (65%) meniscal tears with microfracture healed completely. This comparison also showed statistical significance ($P<.001$) (**Table 2**). The difference between the type of meniscal injury created and the rate of healing ($P<.49$) was not statistically significant.

## Discussion

The meniscus is an integral component of the knee joint and is essential to healthy knee function.[1,2,8] Meniscectomy results in predictable degenerative changes within the knee joint.[4-8] Preservation of meniscal tissue is preferable, but not all meniscal tears heal and many are not amendable to repair. Meniscal tears that occur in the peripheral third zone are believed to have the best chance of complete healing after repair. Meniscal tears in the middle third have variable rates of healing, and meniscal tears that occur in the central third have very poor healing capacity.[30] Other factors that influence surgical decision making include tear size, tear chronicity, knee stability, patient age, and anticipated patient compliance with postoperative weight-bearing restrictions.[4,16]

Meniscal healing can be divided into 3 phases: inflammation, repair, and remodeling.[19] These phases require delivery of mediating factors and cell types that are critical to the healing process.[16,19] These mediators include platelet-derived growth factor, insulin-like growth factor, and transforming growth factor.[16,19] These factors are present in bone marrow and may be responsible for the disparate healing rates noted between meniscal tears repaired with and without concomitant ACL reconstruction.[12,14,16] Preliminary studies have shown promising results for meniscal tissue regeneration with growth factors, but these techniques are not readily available for the treatment of meniscal injuries.[30,31] Studies in other animal models have shown improved meniscal healing with fibrin clot and autologous marrow or blood products.[18,32,33]

Freedman et al[16] proposed a technique using microfracture to release marrow elements into the knee to augment meniscal repair. Autologous growth factors and pluripotent mesenchymal cells are present in bone marrow and may enhance meniscal healing.[16,18] The current study adapted the technique described by Freedman et al[16] to a previously validated goat model in an attempt to evaluate the effectiveness of supplemental microfracture in the setting of isolated meniscal tear.[21,23,24,26,27]

The results of this study suggest that release of bleeding bone marrow elements


Copyright © SLACK Incorporated

into the knee with microfracture promotes meniscal healing in a goat model. Meniscal tears healed in 87% of menisci treated with marrow-stimulating microfracture vs only 29% without microfracture. These results are encouraging because microfracture is a simple procedure that can be performed with little extra equipment, no new technical skills, minimal increase in operative time, and little morbidity to the patient.

This study shows improved healing in meniscal injuries treated with microfracture and provides strong evidence that bone marrow elements provide biologic enhancement in healing meniscal injuries. The strength of this study lies in its prospective, randomized, blinded design. The use of direct visualization of meniscal lesions at necropsy compares favorably with the gold standard of second-look arthroscopy that was used in earlier meniscal research. A limitation of the study is its use of an animal model. Although the goat model has been used extensively and was validated in previous research, it does not represent an exact match to human anatomy.[18,21-24,26,27,34] Additionally, the surgical technique used has inherent weaknesses. Most meniscal repair surgery is arthroscopic and includes placement of a stitch or an anchor. Tears undergoing repair are often larger than those that were created in this study. In addition, this study used an open technique to create small peripheral tears. No formal repair was attempted. The addition of a meniscal repair or the creation of a larger meniscal tear may have led to different results.

## Conclusion

In a goat model, the introduction of bleeding bone marrow elements into the knee through microfracture significantly improved the meniscal healing rates of small peripheral meniscal tears compared with a control group. Concomitant microfracture of the intracondylar notch and/or off the weight-bearing surface of the femoral condyle may improve meniscal healing rates during meniscal repair, but further research based on human data is needed.

## References


1. Barber FA, McGarry JE. Meniscal repair techniques. *Sports Med Arthrosc.* 2007; 15(4):199-207.
2. McCarty EC, Marx RG, DeHaven KE. Meniscal repair: considerations in treatment and update of clinical results. *Clin Orthop Relat Res.* 2002; 402:122-134.
3. Woo SL, Chan SS, Yamaji T. Biomechanics of knee ligament healing, repair and reconstruction. *J Biomech.* 1997; 30(5):431-439.
4. Arnoczky SP, Warren RF. Microvasculature of the human meniscus. *Am J Sports Med.* 1982; 10(2):90-95.
5. Lynch MA, Henning CE, Glick KR Jr. Knee joint surface changes: long-term follow-up of meniscus tear treatment in stable anterior cruciate reconstructions. *Clin Orthop Relat Res.* 1983; 172:148-153.
6. Fairbank TJ. Knee joint changes after meniscectomy. *J Bone Joint Surg Br.* 1948; 30(4):664-670.
7. Rubman MH, Noyes FR, Barber-Westin SD. Arthroscopic repair of meniscal tears that extend to the avascular zone: a review of 198 single and complex tears. *Am J Sports Med.* 1998; 26(1):87-95.
8. Turman KA, Diduch DR. Meniscal repair: indications and techniques. *J Knee Surg.* 2008; 21(2):154-162.
9. Bedi A, Raphael B, Maderazo A, Pavlov H, Williams RJ III. Transtibial versus anteromedial portal drilling for anterior cruciate ligament reconstruction: a cadaveric study of femoral tunnel length and obliquity. *Arthroscopy.* 2010; 26(3):342-350.
10. Vidal AF. The Save the Meniscus Society: commentary on an article by Jeffrey J. Nepple, MD, et al.: "Meniscal repair outcomes at greater than five years: a systematic literature review and meta-analysis." *J Bone Joint Surg Am.* 2012; 94(24):e186.
11. Nepple JJ, Dunn WR, Wright RW. Meniscal repair outcomes at greater than five years: a systematic literature review and meta-analysis. *J Bone Joint Surg Am.* 2012; 94(24):2222-2227.
12. Cannon WDJ. The incidence of healing in arthroscopic meniscal repairs in anterior cruciate ligament-reconstructed knees versus stable knees. *Am J Sports Med.* 1992; 20(2):176-181.
13. Ishimura M, Ohgushi H, Habata T, Tamai S, Fujisawa Y. Arthroscopic meniscal repair using fibrin glue: Part I. Experimental study. *Arthroscopy.* 1997; 13(5):551-557.
14. Cannon WD Jr. Arthroscopic meniscal repair. In: McGinty JB, Caspari RB, Jackson RW, Poehling, eds. *Operative Arthroscopy.* Philadelphia, PA: Lippincott-Raven; 1996:299-315.
15. Cooper DE, Arnoczky SP, Warren RF. Arthroscopic meniscal repair. *Clin Sports Med.* 1990; 9(3):589-607.
16. Freedman KB, Nho SJ, Cole BJ. Marrow stimulating technique to augment meniscus repair. *Arthroscopy.* 2003; 19(7):794-798.
17. Morgan CD, Wojtys EM, Casscells CD, Casscells SW. Arthroscopic meniscal repair evaluated by second-look arthroscopy. *Am J Sports Med.* 1991; 19(6):632-637.
18. LaPrade RF, Kimber KA, Wentorf FA, Olson EJ. Anatomy of the posterolateral aspect of the goat knee. *J Orthop Res.* 2006; 24(2):141-148.
19. Anz AW, Rodkey WG. Biological enhancement of meniscus repair and replacement. *Sports Med Arthrosc.* 2012; 20(2):115-120.
20. Namdari S, Baldwin K, Anakwenze O, Park MJ, Huffman GR, Sennett BJ. Results and performance after microfracture in National Basketball Association athletes. *Am J Sports Med.* 2009; 37(5):943-948.
21. Hospodar SJ, Schmitz MR, Golish SR, Ruder CR, Miller MD. FasT-Fix versus inside-out suture meniscal repair in the goat model. *Am J Sports Med.* 2009; 37(2):330-333.
22. Jackson DW, Lalor PA, Aberman HM, Simon TM. Spontaneous repair of full-thickness defects of articular cartilage in a goat model: a preliminary study. *J Bone Joint Surg Am.* 2001; 83(1):53-64.
23. Miller MD, Kline AJ, Jepsen KG. "All-inside" meniscal repair devices: an experimental study in the goat model. *Am J Sports Med.* 2004; 32(4):858-862.
24. Miller MD, Ritchie JR, Gomez BA, Royster RM, DeLee JC. Meniscal repair: an experimental study in the goat. *Am J Sports Med.* 1995; 23(1):124-128.
25. Port J, Jackson DW, Lee TQ, Simon TM. Meniscal repair supplemented with exogenous fibrin clot and autogenous cultured marrow cells in the goat model. *Am J Sports Med.* 1996; 24(4):547-555.
26. Ritchie JR, Miller MD, Bents RT, Smith DK. Meniscal repair in the goat model: the use of healing adjuncts on central tears and the role of magnetic resonance arthrography in repair evaluation. *Am J Sports Med.* 1998; 26(2):278-284.
27. Zhang Z, Arnold JA, Williams T, McCann B. Repairs by trephination and suturing of longitudinal injuries in the avascular area of the meniscus in goats. *Am J Sports Med.* 1995; 23(1):35-41.
28. Ahn JH, Lee YS, Yoo JC, Chang MJ, Koh KH, Kim MH. Clinical and second-look arthroscopic evaluation of repaired medial meniscus in anterior cruciate ligament-reconstructed knees. *Am J Sports Med.* 2010; 38(3):472-477.
29. Horibe S, Shino K, Nakata K, Maeda A,

Nakamura N, Matsumoto N. Second-look arthroscopy after meniscal repair: review of 132 menisci repaired by an arthroscopic inside-out technique. *J Bone Joint Surg Br.* 1995; 77(2):245-249.

30. Imler SM, Doshi AN, Levenston ME. Combined effects of growth factors and static mechanical compression on meniscus explants biosynthesis. *Osteoarthritis Cartilage.* 2004; 12(9):736-744.
31. Buma P, Ramrattan NN, van Tienen TG, Veth RP. Tissue engineering of the meniscus. *Biomaterials.* 2004; 25(9):1523-1532.
32. Bradley MP, Fadale PD, Hulstyn MJ, Muirhead WR, Lifrak JT. Porcine small intestine submucosa for repair of goat meniscal defects. *Orthopedics.* 2007; 30(8):650-656.
33. Fox JM, Rintz KG, Ferkel RD. Trephination of incomplete meniscal tears. *Arthroscopy.* 1993; 9(4):451-455.
34. Lietman SA, Hobbs W, Inoue N, Reddi AH. Effects of selected growth factors on porcine meniscus in chemically defined medium. *Orthopedics.* 2003; 26(8):799-803.



COPYRIGHT © SLACK INCORPORATED