

Exposure of the Distal Humerus Using a Triceps Hemi-peel Approach

BRIAN F. GROGAN, MD; JAMES A. BLAIR, MD; ROBERT E. BLEASE, MD; MICKEY S. CHO, MD; JOSEPH R. HSU, MD

abstract

Full article available online at Healio.com/Orthopedics

This study evaluates the exposure of the distal humerus articular surface obtained using a triceps hemi-peel approach versus the triceps-flexor carpi ulnaris (TRIFCU) approach. Twelve cadaveric upper extremity specimens were dissected using a lateral-to-medial hemi-peel modification of the TRIFCU approach to the elbow. After completing the hemi-peel exposure, the visible border of the articular surface was marked with a permanent ink pen. The dissection was continued to complete a standard TRIFCU approach, and the visible border of the exposure was again marked. The elbow was disarticulated, and calibrated digital images were taken to quantify the humeral surface area exposed through each approach. During both approaches, the surgeon's ability to visualize the intertrochlear groove, medial crista anterior crest, medial crista posterior crest, anterior capitulum, and posterior capitulum was recorded. No difference was found in the surgeons' ability to identify the 5 designated anatomic landmarks using the hemi-peel versus the TRIFCU approach. The TRIFCU exposed an average of 6.68 cm² of the trochlear articular surface, whereas the hemi-peel approach exposed an average of 5.93 cm². The average difference between the exposures was 0.75 cm² ($P < .001$), or 12.5%. The hemi-peel and TRIFCU approaches to the elbow both allow excellent visualization of the distal humerus articular surface. The hemi-peel exposure is a useful approach for the accurate reduction and fixation of displaced intra-articular distal humerus fractures.

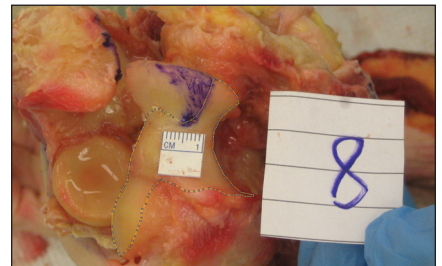


Figure: Photograph of the disarticulated elbow with the articular exposure of the hemi-peel approach outlined.

The authors are from the Department of Orthopedics and Rehabilitation (BFG), Carl R. Darnall Army Medical Center, Fort Hood, Texas; the Department of Orthopaedics and Rehabilitation (JAB), William Beaumont Army Medical Center, El Paso, Texas; the United States Army Tropic Test Center/Ryder Trauma Center (REB), Miami, Florida; the Department of Orthopedics and Rehabilitation (MSC), San Antonio Military Medical Center, Fort Sam Houston, Texas; and the Department of Orthopaedic Surgery (JRH), Carolinas Medical Center, Charlotte, North Carolina.

The authors have no relevant financial relationships to disclose.

Institutional research support was provided by The Geneva Foundation. This study was funded by the US Army Institute of Surgical Research. The views expressed in this manuscript are those of the authors and do not reflect the official policy of the Department of Army, Department of Defense, or US Government. All authors are employees of the US government. This work was prepared as part of their official duties and as such, there is no copyright to be transferred.

Correspondence should be addressed to: Brian F. Grogan, MD, Department of Orthopedics and Rehabilitation, Carl R. Darnall Army Medical Center, 3600 Darnall Loop, Fort Hood, TX 76544 (brian.f.grogan.mil@mail.mil).

Received: October 4, 2013; Accepted: October 16, 2013; Posted: May 14, 2014.

doi: 10.3928/01477447-20140430-56

Anatomic reduction and fixation of displaced intra-articular distal humerus fractures requires adequate visualization of the articular surface. Commonly used surgical approaches include variations of the transolecranon osteotomy approach, bilaterotricipital/paratricipital approach, and triceps reflecting approach to the distal humerus.¹⁻⁶ Anatomic studies have documented the percentage of distal humerus articular exposure achieved using the transolecranon osteotomy, bilaterotricipital, and Bryan and Morrey triceps reflecting approaches.^{7,8} The transolecranon osteotomy and triceps reflecting approaches provide superior visualization compared with the bilaterotricipital approach.^{7,8}

Complications of transolecranon osteotomy include nonunion of the osteotomy site, heterotopic ossification, and symptomatic hardware.⁹⁻¹¹ The bilaterotricipital/paratricipital approach was associated with a high incidence of articular surface malreduction in a small series of AO/ASIF type C3 fractures.^{12,13} Complete reflection of the triceps is associated with extensor mechanism weakness or failure and ulnar nerve dysfunction when the reflection is completed in a medial to lateral direction.¹⁴⁻¹⁶

The previously described triceps-flexor carpi ulnaris (TRIFCU) approach is a variation of the classic triceps reflecting approach. The TRIFCU involves complete reflection of the triceps periosteal sleeve from the proximal ulna in a lateral to medial direction and release of the anconeus insertion to expose the distal humerus articular surface.¹⁷ The lateral-to-medial approach may decrease the risk of ulnar nerve complications, but the complete elevation of the triceps insertion may also predispose patients to the same extensor mechanism weakness or failure associated with classic medial to lateral reflection.

An ideal approach to the distal humerus articular surface would provide the exposure gained using a transolecranon osteotomy or triceps reflecting approach,

while maintaining the triceps insertion as in the bilaterotricipital/paratricipital approach. Such an approach would avoid the need for hardware and be laterally based to exploit the greater natural laxity of the lateral elbow ligamentous constraints to improve exposure.¹⁸ A novel hemi-peel modification of the TRIFCU limits the dissection to 50% of the triceps insertion and avoids complete reflection of the extensor mechanism. The purpose of this study was to evaluate the exposure of the distal humerus articular surface obtained using a triceps hemi-peel approach compared with the TRIFCU approach.

MATERIALS AND METHODS

Hemi-peel Surgical Approach

The limb is positioned over a bump placed in the antecubital fossa to approximate the usual operating conditions in which a posterior approach to the elbow is performed. The initial steps of the hemi-peel exposure are identical to those of the TRIFCU procedure, as described by Deakin and Deshmukh.¹⁷ A posterior midline incision is made over the elbow, and the skin and subcutaneous tissue are reflected medially and laterally. A plane is developed between the lateral border of the triceps and the lateral intermuscular septum. The lateral border of the triceps insertion on the olecranon is identified. The anconeus is located lateral to this plane, and its distal insertion is detached and reflected first proximally and then medially with the triceps. The anconeus is elevated off the joint capsule superficial to the radial collateral ligament and lateral ulnar collateral ligament. This exposes the capsuloligamentous complex over the lateral border of the ulna and the capitulum.

The triceps is then reflected from lateral to medial by releasing the lateral 50% of the triceps osteoperiosteal sleeve from the proximal ulna starting medial to the lateral ulnar collateral ligament. The periosteal sleeve should extend 3 to 5 cm distal to the tip of the olecranon. A sharp Hohmann retractor is placed posterior un-

der the triceps tendon and across to the medial epicondyle. A joker or freer elevator is placed carefully through the joint to expose the medial edge of the medial crista of the trochlea. Under direct visualization, a baby Hohmann retractor is then placed across the medial crista of the trochlea to tilt and retract the proximal ulna. The intact ulnar collateral ligament serves as the pivot point for this tilting of the ulna. Closure of this approach consists of a single, absorbable suture placed at the tip of the anconeus, followed by closure of the skin. No anchoring or repair of the triceps osteoperiosteal sleeve is performed.

Study Design

Twelve fresh frozen cadaveric upper extremity forequarter specimens were used. None of the specimens showed evidence of prior trauma, surgery, or arthrofibrosis. A fellowship-trained hand surgeon (M.S.C.) performed all approaches. A hemi-peel approach was completed as described. After completion of the hemi-peel approach, a permanent ink pen was used to mark the distal/anterior boarder of the exposed distal humeral articular surface. The surgeons' ability to visualize 5 predetermined anatomic landmarks commonly used in the reduction of distal humerus fractures—intertrochlear groove, medial crista anterior crest, medial crista posterior crest, anterior capitulum, and posterior capitulum—was recorded. A calibrated, digital axial photograph of the distal humeral articular surface was taken (**Figure 1**).¹⁹ The remaining medial 50% of the triceps periosteal sleeve was then released from the proximal ulna and reflected laterally to convert the hemi-peel approach to the full TRIFCU approach. The Hohmann retractor was replaced and the distal/anterior boarder of the humeral articular surface was again marked with permanent ink. The surgeons' ability to visualize the 5 predetermined anatomic landmarks was again recorded and a second calibrated, digital axial photograph of

the distal humeral articular surface was taken (**Figure 2**).

After completion of both exposures, each elbow was disarticulated. The area between the marked borders of the hemi-peel and TRIFCU approaches was inked with a permanent pen. The images obtained with the hemi-peel and TRIFCU approaches were analyzed using ImageJ (National Institutes of Health, Bethesda, Maryland) software to quantify the total humeral area exposed using each approach. A Student's *t* test was used to determine significance ($P < .05$).

RESULTS

No difference was found in the surgeons' ability to identify the 5 designated anatomic landmarks using a hemi-peel or TRIFCU approach. Both surgical approaches allowed similar visualization of the intertrochlear groove, medial crista posterior crest, and posterior capitulum. The medial crista anterior crest and anterior capitulum were not visible on either approach. The TRIFCU provided an average of 6.68 cm² (range, 4.72-8.53 cm²; standard deviation, 1.24 cm²) of articular exposure. The hemi-peel approach provided an average of 5.93 cm² (range, 4.40-7.79 cm²; standard deviation, 1.05 cm²) of articular exposure. The average difference of articular exposure between the surgical approaches was 0.75 cm² ($P < .001$), or 12.5%. The area of additional inked area of articular exposure was consistently located along the most distal aspect of the medial crista in all specimens (**Figure 3**).

DISCUSSION

The results of this study demonstrate equivalent visualization of the intertrochlear groove, medial crista posterior crest, and posterior capitulum using a hemi-peel modification of the lateral-to-medial triceps reflecting TRIFCU approach. Neither approach exposed the medial crista anterior crest and anterior capitulum. The TRIFCU exposed an average of 0.75 cm² ($P < .001$) more of the trochlear articular

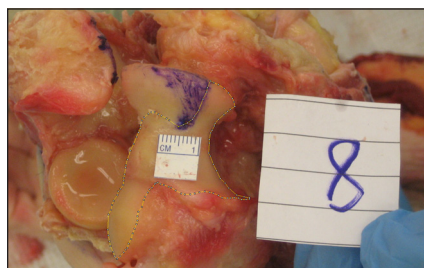


Figure 1: Photograph of the disarticulated elbow with the articular exposure of the hemi-peel approach outlined.

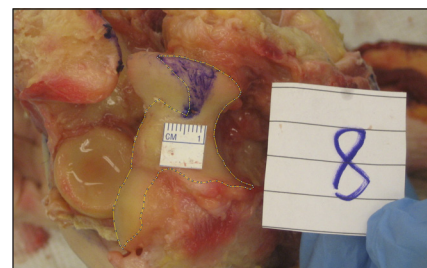


Figure 2: Photograph of the disarticulated elbow with the articular exposure of the triceps-flexor carpi ulnaris approach outlined.

surface than did the hemi-peel approach. It is unclear whether the additional 12.5% of exposure provided by the TRIFCU would lead to clinically significant differences in fracture reduction and stabilization.

Previous anatomic studies comparing surgical exposures have demonstrated that the transolecranon osteotomy exposes 52% to 57% of the distal humerus articular surface (**Table**).^{7,8} The bilaterotricipital approach exposes only 26% of the surface and limits access to only the posteromedial and posterolateral aspects of the trochlea.⁷ The triceps reflecting approach, as described by Bryan and Morrey,⁸ exposes 46% of the articular surface; this is 11% less than osteotomy, but this difference was not found to be statistically significant ($P > .05$).

The greater visualization attained using the transolecranon osteotomy is not without risk; complications include nonunion of the osteotomy site, heterotopic ossification, and symptomatic hardware.^{9,10} Complications are largely due to technical errors and may be avoided by strict adherence to described surgical techniques.¹¹ However, the overall complication rates remain high in this technically demanding approach.

The bilaterotricipital/paratricipital approach has been associated with infrequent cases of ulnar nerve palsy, as well as fracture malreduction.²⁰ Erpelding et al²¹ noted ulnar nerve complications in 2 of 24 patients managed with an extensor mechanism-on distal humerus approach, as well as an average 10% decrease in

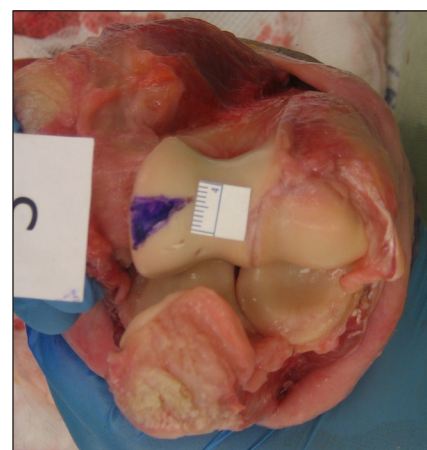


Figure 3: Photograph of the disarticulated elbow with the inked area present on the medial crista. The marked articular surface represents the difference in exposure between the hemi-peel and triceps-flexor carpi ulnaris approach.

elbow extension strength. In addition, the authors found it necessary to convert to an olecranon osteotomy to improve fracture visualization in 3 of 42 cases.²¹ This retrospective study likely underestimates the actual rate conversion from bilaterotricipital/paratricipital approach to an olecranon osteotomy secondary to selection bias; 19 of 79 distal humerus fractures were excluded in the study because they were treated initially with an olecranon osteotomy.²¹ A report by Ali et al¹² cautions against the use of the bilaterotricipital/paratricipital approach for AO/ASIF type C3 fractures. In their series, 3 of 5 patients with type C3 fractures were malreduced (intra-articular step-off greater than 3 mm). Malreduction was attributed to poor

Table

Comparison of Distal Humerus Articular Surface Exposure

Study and Approach	Articular Surface Exposed ^a
Dakouré et al ⁷	
Bilaterotricipital	26
Triceps splitting	37
Olecranon osteotomy	52
Wilkinson and Stanley ⁸	
Triceps splitting	35
Triceps reflecting	46
Olecranon osteotomy	57

^aPercentage of entire articular surface.

visualization of the articular surface using the bilaterotricipital/paratricipital approach.¹²

Many variations of the triceps reflecting approach have been reported. These approaches all involve complete reflection of the triceps osteoperiosteal sleeve from the proximal ulna to expose the distal humerus articular surface. The classic Bryan-Morrey medial-to-lateral triceps reflecting approach has been used to successfully treat complex intracondylar fractures of the distal humerus,²² but the approach has been associated with extensor mechanism weakness or failure¹⁴⁻¹⁶ and ulnar nerve dysfunction.^{11,16} The triceps-reflecting anconeus pedicle (TRAP) approach also involves medial-to-lateral reflection of the triceps insertion but adds a modified Kocher approach that preserves the lateral collateral and annular ligaments while elevating the anconeus from the ulna.⁶

In a series of 11 patients with intercondylar distal humerus fractures treated with open reduction and internal fixation through a TRAP approach, 2 patients developed transient ulnar nerve paresthesias.⁵ The authors noted a decrease in elbow extensor peak torque of 10.3 Nm (80.1 Nm in the uninjured extremity vs 69.8 Nm in the injured extremity, recorded at 60° per second).⁵ The TRIFCU approach, as described by Deakin and

Deshmukh,¹⁷ reflects the triceps insertion in a lateral to medial direction and releases the anconeus insertion to expose the distal humerus articular surface. Currently, to the authors' knowledge no published studies report outcome data on the use of the TRIFCU approach. It is possible that a lateral-to-medial approach may decrease the risk of ulnar nerve complications, but the complete reflection of the triceps insertion may also predispose patients to the same extensor mechanism weakness or failure associated with other complete reflection-type approaches.

The hemi-peel modification of the TRIFCU represents a compromise between the excellent articular surface visualization provided by transolecranon osteotomy and triceps reflecting approaches and the extensor mechanism preservation of the bilaterotricipital/paratricipital approaches. The hemi-peel attempts to mitigate the risk of extensor mechanism weakness and ulnar nerve injury by limiting dissection to the lateral 50% of the triceps periosteal insertion on the proximal ulna. It exploits the greater laxity of the lateral structures of the elbow as a window for visualization of the articular surface. No osteotomy or hardware is required, and the medial insertion of the triceps is maintained.

This study is limited by the use cadaveric specimens. The tissue characteristics

of the specimens differ from those of live patients and may affect the exposure achieved by the approaches. In addition, the photographs used to calculate the distal humeral exposure are a 2-dimensional representation of a 3-dimensional structure and likely represent an underestimation of the actual exposed articular surface area.

CONCLUSION

The hemi-peel modification of the TRIFCU offers excellent visualization of the distal humerus articular surface, while limiting dissection to the lateral 50% of the triceps osteoperiosteal sleeve from the proximal ulna. Prospective research comparing the complication rates and functional outcomes of the hemi-peel and TRIFCU approaches is needed.

REFERENCES

- Hoppenfeld S, deBoer P. The elbow. In: Hoppenfeld S, deBoer P, eds. *Surgical Exposures in Orthopaedics: The Anatomic Approach*. Philadelphia, PA: Lippincott Williams & Wilkins; 2003:106-110.
- Alonso-Llames M. Bilaterotricipital approach to the elbow. *Acta Orthop Scand*. 1972; 43:479-490.
- Schildhauer TA, Nork SE, Mills WJ, Henley MB. Extensor mechanism-sparing paratricipital posterior approach to the distal humerus. *J Orthop Trauma*. 2003; 17:374-378.
- Bryan RS, Morrey BF. Extensive posterior exposure of the elbow: a triceps-sparing approach. *Clin Orthop Relat Res*. 1982; (166):188-192.
- Ozer H, Solak S, Turanlı S, Baltacı G, Colakoglu T, Bolukbasi S. Intercondylar fractures of the distal humerus treated with the triceps-reflecting anconeus pedicle approach. *Arch Orthop Trauma Surg*. 2005; 125:469-474.
- O'Driscoll SW. The triceps-reflecting anconeus pedicle (TRAP) approach for distal humeral fractures and nonunions. *Orthop Clin North Am*. 2000; 31:91-101.
- Dakouré PW, Ndiaye A, Ndoye JM, et al. Posterior surgical approaches to the elbow: a simple method of comparison of the articular exposure. *Surg Radiol Anat*. 2007; 29:671-674.
- Wilkinson JM, Stanley D. Posterior surgical approaches to the elbow: a comparative anatomic study. *J Shoulder Elbow Surg*. 2001; 10:380-382.
- Gainor BJ, Moussa F, Schott T. Healing rate

- of transverse osteotomies of the olecranon used in reconstruction of distal humerus fractures. *J South Orthop Assoc.* 1995; 4:263-268.
10. McKee MD, Kin J, Kebaish K, Stephen DJ, Kreder, HJ, Schemitsch EH. Functional outcome after open supracondylar fractures of the humerus: the effect of the surgical approach. *J Bone Joint Surg Br.* 2000; 82:646-651.
 11. Morrey BF, Bryan RS. Complications of total elbow arthroplasty. *Clin Orthop Relat Res.* 1982; (170):204-212.
 12. Ali AM, Hassanin EY, El-Ganainy AE, Abd-Elmola T. Management of intercondylar fractures of the humerus using the extensor mechanism-sparing paratricipital posterior approach. *Acta Orthop Belg.* 2008; 74:747-752.
 13. Muller ME, Nazarian S, Koch P. *The AO Classification of Long Bones Fractures.* Berlin: Springer; 1990.
 14. Pierce TD, Herndon JH. The triceps preserving approach to total elbow arthroplasty. *Clin Orthop Relat Res.* 1998; (354):144-152.
 15. Celli A, Arash A, Adams R, Morrey BF. Triceps insufficiency following total elbow arthroplasty. *J Bone Joint Surg Am.* 2005; 87:1957-1964.
 16. Hildebrand KA, Patterson SD, Regan WD, MacDermid JC, King GJ. Functional outcome of semiconstrained total elbow arthroplasty. *J Bone Joint Surg Am.* 2000; 82:1379-1386.
 17. Deakin DE, Deshmukh SC. The triceps-flexor carpi ulnaris (TRIFCU) approach to the elbow. *Ann R Coll Surg Engl.* 2010; 92:240-242.
 18. Regan WD, Korinek SL, Morrey BF, An KN. Biomechanical study of ligaments around the elbow joint. *Clin Orthop Relat Res.* 1991; (271):170-179.
 19. Blair JA, Stinner DJ, Kirby JM, et al. Quantification of femoral neck exposure through a minimally invasive Smith-Petersen approach. *J Orthop Trauma.* 2010; 24:355-358.
 20. Jamali AR, Ghulam M, Saghir A. Extensor mechanism sparing approach to the elbow for reduction and internal fixation of intercondylar fracture of the humerus. *J Pak Med Assoc.* 1999; 49:164-167.
 21. Erpelding JM, Mailander A, High R, Mormino MA, Fehringer EV. Outcomes following distal humeral fracture fixation with an extensor mechanism-on approach. *J Bone Joint Surg Am.* 2012; 94:548-553.
 22. Ek ET, Goldwasser M, Bonomo AL. Functional outcome of complex intercondylar fractures of the distal humerus treated through a triceps-sparing approach. *J Shoulder Elbow Surg.* 2008; 17:441-446.